

Valley Fever in the UK? The importance of a travel history

EDUCATION

AUTHOR

Laura J. Cunliffe

Hull York Medical School

Dr Ian Renwick

MBBS, FRCR

Consultant Radiologist

Scarborough General Hospital

Address for correspondence

Laura Cunliffe

Hull York Medical School

John Hughlings Jackson Building

University of York

Heslington, York, YO10 5DD

Email: hyljc@hyms.ac.uk

No conflicts of interest to declare

Special thanks to

Dr Craig Bratten

Consultant Histopathologist

York District Hospital

ABSTRACT

Summary

Coccidioidomycosis, also known as Valley Fever, is a fungal infection caused by the inhalation of spores, and is endemic in the Southwestern United States, regions of Mexico, Central America and South America. (1) It therefore came as a surprise to isolate this infection from a patient in a seaside town in North Yorkshire, UK. Coccidioidomycosis is caused by either *Coccidioides immitis* or *Coccidioides posadasii*, and once inhaled they are highly infectious, and can cause a wide variation in clinical manifestation and imaging findings. (1) Most infections primarily involve the lungs, and are self-limiting and resolve over a period of weeks to months. (1) Occasionally the infection can spread to cause a very serious disseminated disease. The radiographic findings can be nonspecific and variable, often raising concern for many differential diagnoses such as malignancy, other infections or granulomatous conditions. (1, 3)

Relevance

This was an interesting case of a female patient in the UK presenting with nonspecific respiratory symptoms, and eventually being diagnosed with a fungal infection typically found in the Southwestern United States.

Take Home Messages

It highlights the importance of enquiring about a travel history, and conducting appropriate imaging, even when the initial picture points towards a less exotic, more sinister diagnosis.

INTRODUCTION

Coccidioidomycosis, also known as Valley Fever, is a fungal infection caused by either *Coccidioides immitis* or *Coccidioides posadasii*, which are dimorphic fungi found in the soil in endemic areas; commonly the San Joaquin Valley in California, USA, Southwest USA and Northern Mexico, but increasingly commonly found in non-endemic areas, as in this case. (1,2,4,5,6) The hyphal form of the organism proliferates in the soil as a mycelium during the rainy season and dies in the dry period. (3) The highly infectious spores, called anthroconidia, are released into the air when the soil is disturbed by agricultural work, landscaping or windy conditions. (1) Once in the air these spores can be inhaled, and are so infectious that one spore is enough to cause clinical infection. (6) Once inside the airway, they swell to produce spherules that rupture to release endospores, which perpetuate infection and inflammation with the lungs being the primary site of infection in 95% of cases. (1,7) Clinical manifestations include a flu-like illness with fatigue, cough, fever, headache, shortness of breath, night sweats, myalgia and arthralgia. Misdiagnosis is common; therefore awareness should be increased to allow for inclusion in the differential diagnosis. For immunosuppressed patients, the disease can be more serious, ranging from the above mentioned Primary Pulmonary Coccidioidomycosis to Chronic Coccidioidomycosis (which develops months to years after contracting the initial disease and can lead to lung scarring) or disseminated Coccidioidomycosis. (1,2,7)

CASE REPORT

A 54 year old lady with no significant past medical history presented to Accident and Emergency with a one week history of feeling generally unwell and lethargic, with 3kg weight loss and diarrhoea. This was accompanied by a two day history of shortness of breath, fever, petechial rash on fingers, and swelling and tingling of the lips. The chest X-ray showed a 3cm diameter rounded soft tissue lesion in the right mid-zone with some faint consolidation and no hilar or mediastinal lymphadenopathy (Fig 1). This was thought to be a round pneumonia, but a tumour could not be excluded. A CT of her chest and abdomen with contrast showed a 2.7cm diameter solid spiculated lesion in the apex of the right lower lobe, against the oblique fissure, with no air bronchogram through it (Fig 2). There was some ground glass shadowing elsewhere in the lower lobe, and a subcentimeter node in the right hilum, along with some minor lymphadenopathy in the mediastinum, all <1cm. Simple liver cysts were noted but no evidence of metastatic disease. Appearances were therefore suggestive of a primary bronchial malignancy. A referral to the respiratory physicians for consideration of a PET, CT and biopsy was suggested. In a roundabout way, it came to the knowledge of the reporting consultant radiologist that this lady had recently been to the Southwestern United States, and had spent some time underground in caves. Consequently, an

addendum was added to the report to suggest that histoplasmosis should be included in the differential. The working diagnoses were now; primary malignancy, histoplasmosis, fungal infection, tuberculosis or another granulomatous process. A CT guided biopsy and bronchoscopy were completed and the specimens were sent for histological and microbiological opinion. Lung biopsy showed spherules containing endospores, suggestive of a diagnosis of Coccidioidomycosis (Fig 3). After discussion with the Tropical Disease specialists, she was commenced on 400mg fluconazole daily for six months. Two months later she had almost completely recovered with only some residual fatigue. Follow up chest X-ray at eight weeks showed considerable improvement, with only a small amount of residual shadowing, with no effusions or hilar/paratracheal lymphadenopathy. Follow-up at 2 months revealed that the patient was almost completely recovered.

DISCUSSION

In endemic areas Coccidioidomycosis causes 15–30% of community acquired pneumonia, and there are vast differences in the appearances on imaging. (8) The most common finding on chest X-ray is a dense homogenous consolidation, occurring in 75% of cases, and can be solitary or multiple areas, suggesting a diagnosis of bacterial pneumonia. (1) Ground glass appearances are common, along with nodular lesions and mediastinal/hilar lymphadenopathy in 20% of cases, again as seen in this case, suggestive of metastatic disease. (1,3) Other findings can include cavities, which in the acute form can look like *Mycobacterium tuberculosis* infection. (3) Pleural effusions are seen in 15–20% of cases, whereas no abnormalities can be found in 20% of other infected individuals. (1,2) Other differential diagnoses to be considered include lung abscesses, lymphoma or a rheumatological condition. (9) CT findings are just as varied, including subtle opacities, lymphadenopathy, and discrete lesions. (1) Common findings include intralobular septal thickening, cavitation, ill-defined nodules and endotracheal or endobronchial Coccidioidal granulomas. (1,5,7,10) CT can also show pericardial disease, pneumatoceles, hydropneumothorax, bronchiectasis and granulomas. (3) MRI images are more useful when assessing the extent of bone, joint and soft tissue involvement in disseminated disease, mainly demonstrating high marrow signal intensity. (3) Other modalities include radioisotope bone scanning and PET-CT scans to indicate bone involvement and active fungal invasion respectively in disseminated disease. (11)

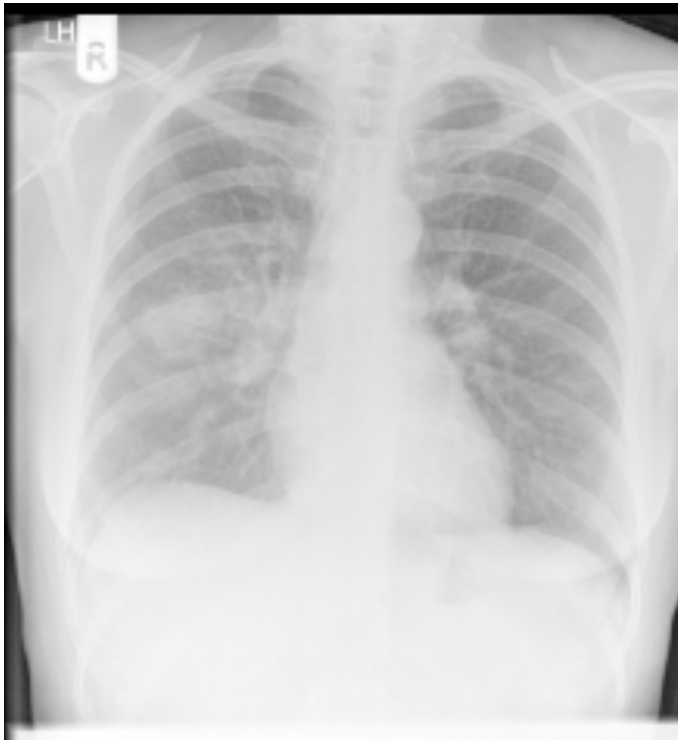


Figure 1
*PA Erect Chest X-Ray, showing
right sided round consolidation*

Figure 2
*CT Thorax, showing spiculated
lesion in right mid-zone*

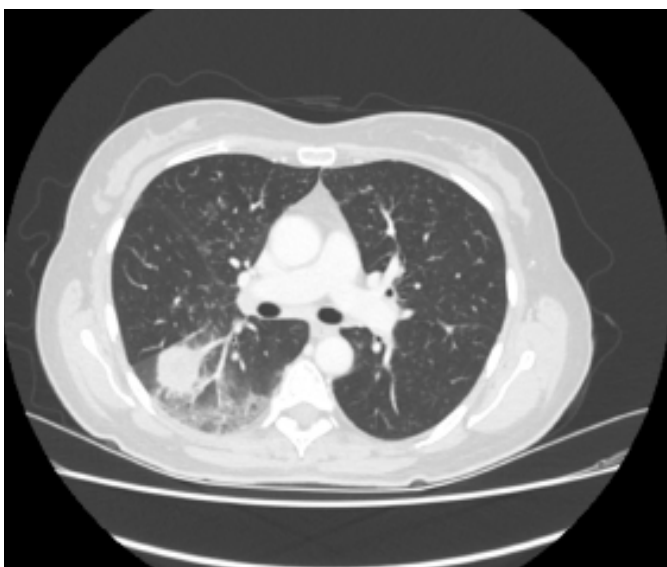
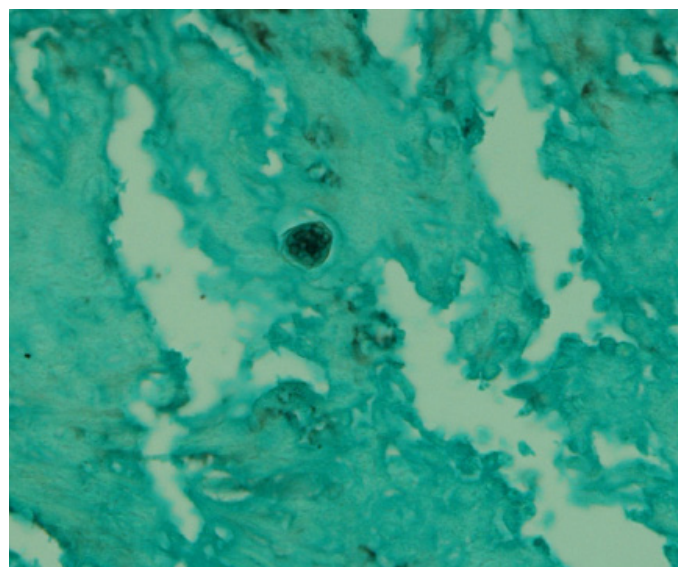


Figure 3
*Grocott Stain 40X, showing
Spherule containing endospores*



CONCLUSION

Coccidioidomycosis infection is very common in endemic areas, but not commonly seen in the UK. However, with the increase in travel, immunocompromise and the use of immunosuppressants, it is becoming more frequently seen in non-endemic areas, including other countries. (1) Therefore familiarity with the imaging characteristics, along with a comprehensive travel history is necessary to be able to consider such exotic diagnoses, obtain biopsies, and initiate appropriate treatment. It is also vital to remember that many tropical diseases can mimic malignancies both on imaging and clinically; thus the importance of rapid biopsy and treatment is essential to avoid delay and subsequent deterioration.

REFERENCES:

- Jude CM, Nayak NB, Patel MK, Deshmukh M, Batra P. Pulmonary coccidioidomycosis: Pictorial review of chest radiographic and CT findings. *RSNA RadioGraphics*. 2014;34(4) [accessed 7 Nov 2016]. Available from: <http://pubs.rsna.org/doi/ref/10.1148/rg.344130134>
- Musil IL, Gilbertson-Dahdal D, Elliott SP. Disseminated coccidioidomycosis in an immunodeficient 16 year old female. *Radiology Case Reports*. 2008; 3(4) [accessed 7 Nov 2016]. Available from: https://www.researchgate.net/publication/244937509_Disseminated_Coccidioidomycosis_in_an_Immunodeficient_16YearOld_Female
<https://doi.org/10.2484/rcr.v3i4.237>
PMid:27303563 PMCID:PMC4897600
- Sharma S, Maycher B. Coccidioidomycosis Imaging. *MedScape*. [accessed 7 Nov 2016]. Available from: <http://emedicine.medscape.com/article/2137779-overview>
- Gupta NA, Iv M, Pandit RP, Patel MR. Imaging manifestations of primary and disseminated coccidioidomycosis. *Applied Radiology. The Journal Of Practical Medical Imaging Management*. 2015 [accessed 7 Nov 2016]. Available from: <http://appliedradiology.com/articles/imaging-manifestations-of-primary-and-disseminated-coccidioidomycosis>
- Centre for disease control and prevention. Valley Fever Awareness CDC features. 2016 [accessed 7 Nov 2016]. Available from: <http://www.cdc.gov/features/valleyfever/>
- Hospenthal DR, Arsura EL, Oppenheimer AP, Thompson GR. Coccidioidomycosis. *MedScape*. 2016 [accessed 13 Nov 2016]. Available from: <http://emedicine.medscape.com/article/215978-overview>
- Skalski M, Weerakkody Y. Pulmonary Coccidioidomycosis. *Radiopaedia.org*. [accessed 7 Nov 2016]. Available from: <https://radiopaedia.org/articles/pulmonary-coccidioidomycosis>
- Centre for disease control and prevention. Valley Fever (Coccidioidomycosis) statistics. *CDC fungal disease*. [accessed 4 Jan 2016]. Available from: <http://www.cdc.gov/fungal/diseases/coccidioidomycosis/statistics.html>
- Hospenthal DR, Arsura EL, Oppenheimer AP, Thompson GR, Bronze BE. Coccidioidomycosis differential diagnoses. *MedScape*. 2016 [accessed 13 Nov 2016]. Available from: <http://emedicine.medscape.com/article/215978-differential>
- Capone D, Marchiori E, Wanke B, Dantas K, Cavalcanti MAS, Filho AD, Esucissato DL, Warszawiak D. Acute pulmonary coccidioidomycosis: CT findings on 15 patients. *The British Institute of Radiology*. 2008; 81(969) [accessed 7 Nov 2016]. Available from: <http://www.birpublications.org/toc/bjr/81/969>
- Hot A, Maunoury C, Poiree S, Lanternier F, Viard JP, Louergue P, Coignard H, Bournoux ME, Suarez F, Rubio MT, Dupont B, Lecuit M, Faraggi M, Lortholary O. Diagnostic contribution of positron emission tomography with fluorodeoxyglucose for invasive fungal infections *Clinical microbiology and infection*. 2011;17(3) [accessed 7 Nov 2016]. Available from: <http://www.sciencedirect.com/science/article/pii/S1198743X14638775>
<https://doi.org/10.1111/j.1469-0691.2010.03301.x>
PMid:20636432



The British Student Doctor is an open access journal, which means that all content is available without charge to the user or his/her institution. You are allowed to read, download, copy, distribute, print, search, or link to the full texts of the articles in this journal without asking prior permission from either the publisher or the author.

bsdj.org.uk



[/thebsdj](https://www.facebook.com/thebsdj)



[@thebsdj](https://twitter.com/thebsdj)



[@thebsdj](https://www.instagram.com/thebsdj)

Journal DOI

10.18573/issn.2514-3174

Issue DOI

10.18573/n.2017.10117

This journal is licensed under a Creative Commons Attribution-NonCommercial-NoDerivatives 4.0 International License. The copyright of all articles belongs to **The British Student Doctor**, and a citation should be made when any article is quoted, used or referred to in another work.



Cardiff University Press
Gwasg Prifysgol Caerdydd

The British Student Doctor is an imprint of Cardiff University Press, an innovative open-access publisher of academic research, where 'open-access' means free for both readers and writers.

cardiffuniversitypress.org